

Aging of the Upper Lip: Part II. Evidence-Based Rejuvenation of the Upper Lip—A Review of 500 Consecutive Cases

Patrick L. Tonnard, M.D.,
Ph.D.

Alexis M. Verpaele, M.D.,
Ph.D.

Lisa E. Ramaut, M.D.

Phillip N. Blondeel, M.D.,
Ph.D.

Ghent, Belgium



Background: Findings from photometric analysis of soft tissue on cranial magnetic resonance imaging demonstrate that the aging upper lip shows significant lengthening, thinning, volume loss, and deepening of the nasolabial folds. In this study, these findings are implemented in a review of 500 cases of upper lip rejuvenation to propose an evidence-based strategy for surgical rejuvenation of the upper lip.

Methods: The charts of 500 consecutive surgical perioral rejuvenation patients treated by the senior authors (P.L.T. and A.M.V.) from 2014 until 2018 were reviewed. The surgical methods of lip lift and fat grafting were described in relation to the cases and the metric data.

Results: Of the 500 patients, 51 had an isolated procedure such as a lip lift (3 percent), lip augmentation (3 percent), augmentation of the nasolabial folds (2 percent), or skin resurfacing (2 percent). The remaining 449 patients underwent combinations of lip lift, augmentation of the lip and nasolabial fold (32 percent), lip lift with augmentation of the lip and nasolabial fold with resurfacing (30 percent), lip augmentation and resurfacing (14 percent), or lip lift and resurfacing (14 percent).

Conclusions: Rejuvenating the upper lip needs to address both lengthening and volume loss. This requires a combination of surgical shortening of the upper lip by a precisely designed lip lift and a differential filling of certain upper lip regions by microfat grafting. The combination of these two modalities works synergistically. (*Plast. Reconstr. Surg.* 143: 1333, 2019.)

CLINICAL QUESTION/LEVEL OF EVIDENCE: Therapeutic, IV.

The perioral area and the periorbital area together play a very important role in the emotional expression of the human face. Consequently, aging in these centropalpebral areas has a major impact on this emotional expression. Although the changes in the aging perioral area are clinically obvious (Fig. 1 and Table 1), the underlying mechanisms of the perioral aging process are poorly understood. The discussion about the relative role of volume loss versus vertical lengthening of the upper lip is still ongoing.¹⁻⁶ Clinically, there are changes in skin quality, shape, and projection of the upper lip; there is loss of

definition of anatomical landmarks such as the vermilion border, Cupid's bow, and philtrum columns; and there is the appearance of nasolabial folds and creases.⁶⁻⁹ All of these features come forth in variable degrees from volume loss during the aging process.^{5,10-14} Vertical photometric

Disclosure: *The authors have no financial interest to declare in relation to the content of this article. No funding was received for the article.*

Supplemental digital content is available for this article. Direct URL citations appear in the text; simply type the URL address into any Web browser to access this content. Clickable links to the material are provided in the HTML text of this article on the *Journal's* website (www.PRSJournal.com).

From the Coupure Centrum for Plastic Surgery; and the Department of Plastic and Reconstructive Surgery, Burn Center, University Hospital Ghent.

Received for publication March 28, 2018; accepted December 12, 2018.

Copyright © 2019 by the American Society of Plastic Surgeons

DOI: 10.1097/PRS.0000000000005589

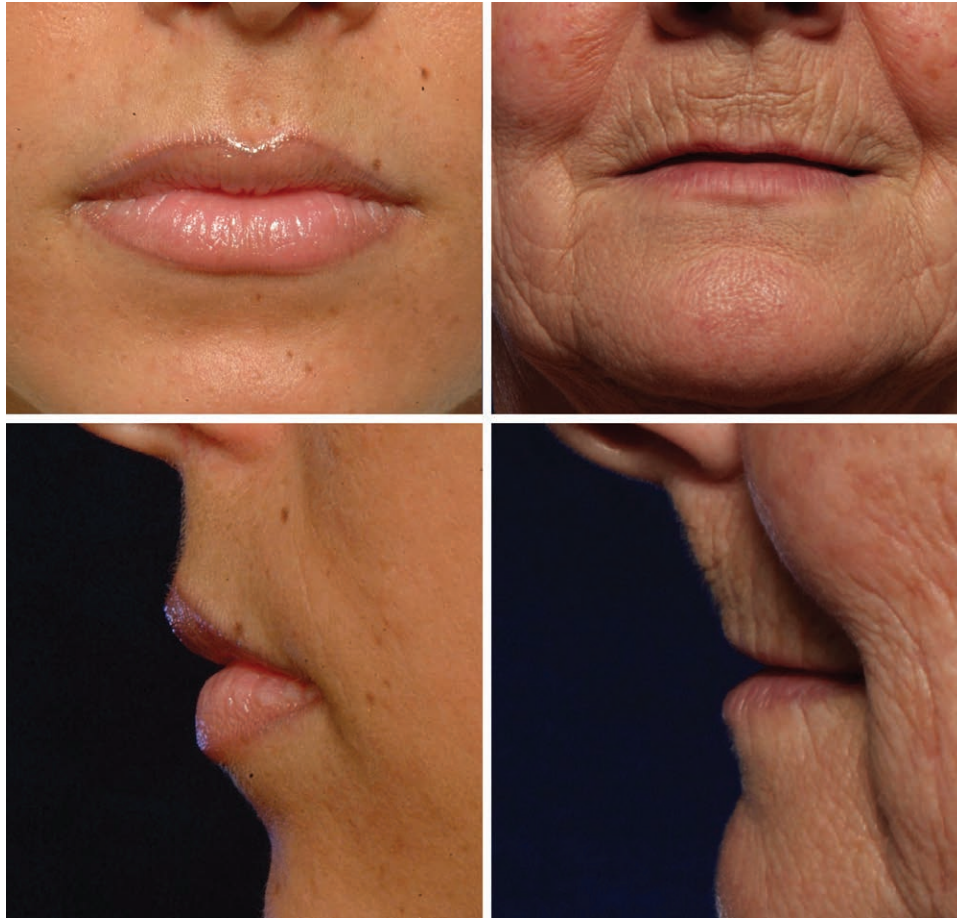


Fig. 1. Clinical comparison of the perioral area of a 20-year-old woman with that of a 60-year-old woman.

analysis of aging faces, in contrast, shows that the upper lip undergoes a consistent and measurable vertical lengthening^{8,15-17} (Fig. 2).

To understand the relative contribution of vertical lengthening versus volume loss in the aging process of the upper lip, a retrospective analysis of metric changes of the upper lip soft tissue by means of magnetic resonance images was undertaken.¹⁸ The results of this study can be summarized as follows: in the time span of the study (approximately 47 years), there is a significant

lengthening, thinning, and volume loss of the upper lip in women and of the sagittal and the parasagittal planes in men. Lengthening is more pronounced in the sagittal plane than in the parasagittal plane through the lateral alar rim: 19.7 percent versus 11.6 percent in women, and 18.4 percent versus 12.1 percent in men. Thinning was most pronounced at the vermiliocutaneous border in the sagittal plane: 40.6 percent in women and 32.7 percent in men, with obvious loss of pouting in both sexes. This thinning was also seen in

Table 1. Comparison of Surface Anatomy of the Young versus Aged Upper Lip

	Young Upper Lip	Aged Upper Lip
Lower-to-upper lip ratio	1:1618	<1:1618
Upper lip projection	Upper lip 1–2 mm anterior to lower	Upper lip equally projected or posterior to lower lip
Vermiliocutaneous border	Well-defined, pouting	Ill-defined, loss of pouting
Cupid's bow	Distinct	Faded
Nasal base to vermilion	Concave	Straight to convex
Philtral columns	Distinct	Faded
Mucosa	Soft, good turgor	Dry, loss of turgor
Skin surface	Smooth, equal tone	Rough, pigmentation, rhytides
Oral commissures	Horizontal of curved upward	Curved downward



Fig. 2. Vertical photometric analysis reveals that the upper lip is the only feature in the centofacial area that sags. All the other anatomical landmarks stay in exactly the same position.

the parasagittal section but was less pronounced: 19.7 percent in women and 11.5 percent in men. The thinning at the nasolabial fold next to the alar rim was more important than in the rest of the lip at the same plane: 25 percent in women and 25.7 percent in men. This suggests a higher differential volume resorption in the nasolabial fold than in the rest of the lip. Volume loss in the sagittal plane was found to be 20.9 percent in women and 17.4 percent in men.¹⁸ These findings suggest the need for a combined differential volumization of certain areas in the upper lip together with a surgical shortening of the vertical height of the upper lip to reconstruct a natural appearing younger upper lip.

In the present study, these findings are combined with a review of 500 cases of upper lip rejuvenation to propose an evidence-based strategy for surgical rejuvenation of the upper lip. This consists of a combination of surgical shortening of the upper lip by a precisely designed lip lift and a differential filling of certain upper lip regions by microfat grafting.

PATIENTS AND METHODS

The charts of 500 consecutive surgical perioral rejuvenation patients treated at the two senior authors' (P.L.T. and A.M.V.) private clinic from October of 2014 until January of 2018 were reviewed. Patient demographics, complications, and clinical results were recorded. All patients in the series were evaluated clinically with a standard postoperative follow-up and by surgeon review of photographs. Patients in this series underwent combinations of lip lift, fat grafting,

and resurfacing techniques, alone or in association with other facial rejuvenation procedures. The procedure was performed under general or local anesthesia. Patients undergoing isolated augmentation of the lip with fillers were excluded from the series. Microfat was used for all the fat grafting procedures, harvested with a 2.4-mm cannula and with 20 sharpened 1-mm diameter holes [Tulip grater cannula harvester; SuperLuerLok (Tulip Medical, San Diego, Calif.)] as described previously.^{19,20} The areas to be grafted and the lip-lift pattern were marked preoperatively with the patient upright.

Surgical Lip-Lifting Technique

Skin Resection Pattern

The magnetic resonance imaging study showed that in addition to the objectifiable significant lengthening of the vertical height of the upper lip with aging in the sagittal plane, a second important finding was the significant lengthening in the parasagittal plane at the alar rim.¹⁸ This parasagittal lengthening was found to be less pronounced (19.7 percent versus 11.59 percent in women; 18.39 percent versus 12.14 percent in men) but still consistently present. This is reflected in our lip-lift design, which includes a concentric resection around the alar rim (Fig. 3).

The superior resection line must traverse the columella exactly at the interface between the two aesthetic units of the columella and the upper lip. The incision must then continue 3 to 5 mm inside the nostril and curve around the alar rim again exactly between the two aesthetic units of the nasal ala and the pyriform fossa. The incision

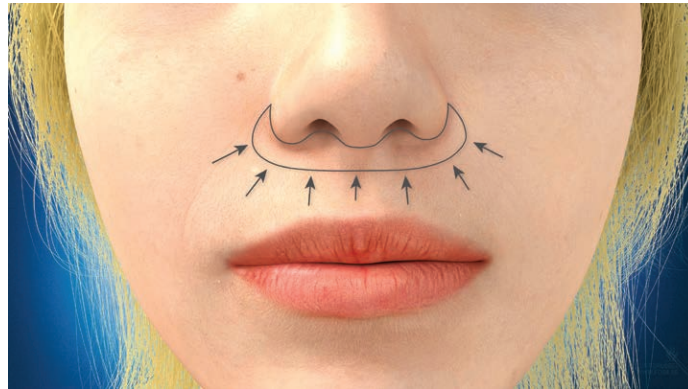


Fig. 3. Proposed resection pattern for a lip lift based on the age-related lengthening of the upper lip in the sagittal and parasagittal planes: the concentric recruitment of skin should be marked, lifting the whole upper lip. The upper incision goes into the nostril sill, resulting in an invisible scar.

must continue high enough to approximately three-fourths of the vertical height of the ala to ensure sufficient lifting of the lateral part of the upper lip. The lower resection line is a linear line connecting the two lateral ends of the incision in a bow-shaped pattern.

Amount of Skin to Be Resected

The position of the lower incision depends on the desired extent of the lip lift and is based mostly on comparison with photographs of the patient at a younger age. When in possession of a good frontal view of the patient at a younger age (e.g., an old passport photograph), one can calculate the proportion between the width of the nose at the alar base and the vertical height of the upper lip.

Because the measurements on cranial magnetic resonance imaging showed no changes with aging in nasal base width, this consistent proportion can be used to calculate the desired length of the lip (Fig. 4), as follows. On the young photograph: Width nasal base/Upper lip length = X . On the patient: Width nasal base/ X = Wanted upper lip length.

Anesthesia

The lip lift can be performed separately, but is often combined with other facial rejuvenation procedures under local or general anesthesia. In case of local anesthesia, the perioral area is numbed by a double nerve block of both infraorbital nerves with additional infiltrative anesthesia (lidocaine 1% plus adrenaline 1:200,000) of the resection pattern. It is best to wait 15 minutes before starting the operation to provide maximum vasoconstriction in this highly vascular region.

Surgical Technique

Before incising the skin, a fine blood suction cannula is prepared because the procedure can be quite bloody and the blood accumulation will obstruct the view of the resection pattern. (See **Video, Supplemental Digital Content 1**, which demonstrates lip-lift surgery, available in the “Related Videos” section of the full-text article on PRSJournal.com or, for Ovid users, available at <http://links.lww.com/PRS/D403>.) We usually start with the cranial incision, as this is the most difficult to perform, especially the intranasal parts. After completing the skin pattern incision, the

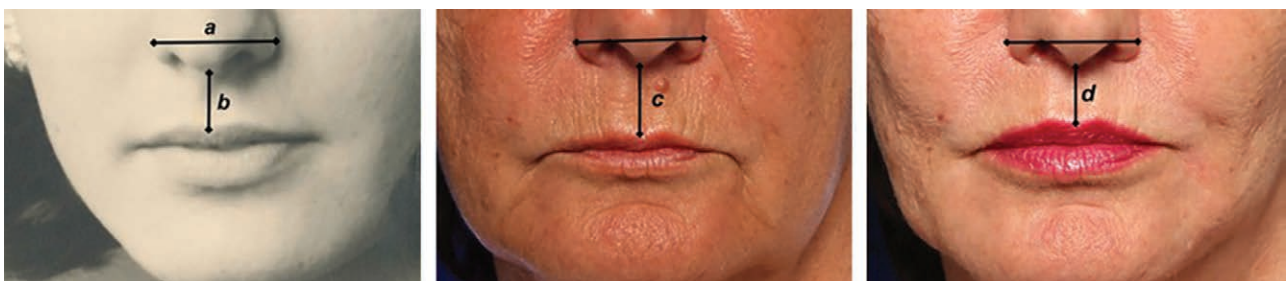
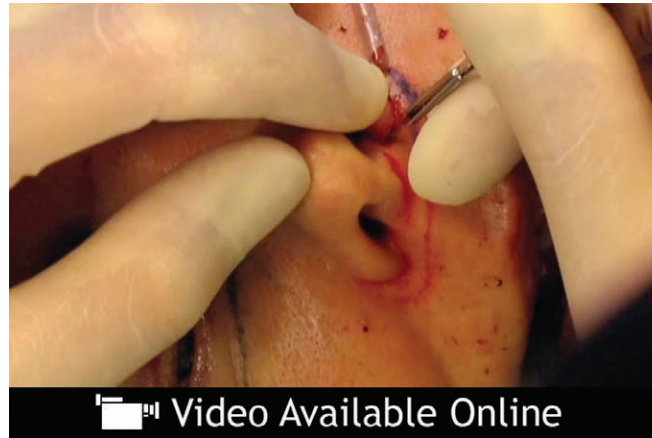

Fig. 4. The proportion between nose width (a) and lip length at a young age (b) can be used to calculate how much should be resected from the aged lip (c) to restore the youthful length of the upper lip (d).



Video. Supplemental Digital Content 1 demonstrates lip-lift surgery, available in the “Related Videos” section of the full-text article on PRSJournal.com or, for Ovid users, available at <http://links.lww.com/PRS/D403>.

fragment is resected in the level above the orbicularis oris muscle with the microneedle electrocautery in coagulation mode. After proper hemostasis, the caudal skin is undermined for 2 mm to promote a good skin edge eversion. Closure of the defect must be performed with extreme precision: five buried subcutaneous polydioxanone 5-0 (Maxon; Ethicon, Inc., Somerville, N.J.) sutures followed by a running horizontal mattress suture of 5-0 monofilament nylon. This suture is not easy to remove, but it is better than an intracutaneous suture with regard to eversion of the skin edges. The nylon suture is removed at day 6 postoperatively.

Microfat Grafting of the Perioral Area

Local infiltration with adrenaline solution (1:650,000) is performed in all treated areas as described previously.

Upper Lip

Based on the results obtained with the magnetic resonance imaging study,¹⁸ rejuvenative volume augmentation of the upper lip can be divided into three categories: lip volume, lip definition, and filling of vertical rhytides (the so-called bar code). For lip volume enhancement, the microfat is delivered with 0.7-mm blunt microcannulas (Tulip Medical) through two puncture holes made with an 18-gauge needle in both oral commissures. The fat is delivered in all layers, with most of the volume deposited in the orbicularis muscle. Bidigital palpation is used to check the homogenous distribution of the injected fat. Minor irregularities can be corrected by gentle bidigital massage.

The puncture holes are not closed. Average volumes are 0.5 to 2.0 cc per hemilip.

For enhancing lip definition and shape, the sharp needle intradermal fat grafting injection technique is used more superficially into the white roll with a 21-gauge sharp needle injection threading the roll and injecting on withdrawal.¹⁹ On average, a volume of 1 cc is injected in the white roll of both the upper and lower lips. The philtrum columns can be enhanced with the same technique. An average of 0.25 cc per column is used.

Vertical rhytides on the upper lip surface can be injected with a 23-gauge needle using the same sharp needle intradermal fat grafting technique. Local infiltration with adrenaline (1:200,000) is used before injection. The individual wrinkles are best marked preoperatively to stay visible after local infiltration. The wrinkle can be squeezed between the index finger and thumb of the non-dominant hand, and injection is always performed in a retrograde fashion at an intradermal level to avoid vascular embolization.

Nasolabial Folds

The results obtained from the magnetic resonance imaging study show that volume loss plays a role in the gradual appearance of the nasolabial fold.¹⁸ The fold showed a significantly greater decrease in tissue thickness in comparison with the rest of the lip. Deep filling of the nasolabial crease is performed perpendicular to the crease with a 0.7-mm microcannula through a puncture hole with an 18-gauge needle. As most of the volume loss is in the canine fossa (Ristow space),²¹ the nasolabial fold is filled in a triangular pattern,

with the base at the alar rim and tip at the corner of the mouth, preventing the formation of a sausage-like deformity in the crease. An additional surgical subcision is often performed using an 18-gauge needle, cutting the retracting ligamentous attachments between the skin and the underlying structures.

RESULTS

Among the 500 patients who underwent a perioral rejuvenation procedure and had their cases reviewed, 470 (94 percent) were women and 30 (6 percent) were men. The mean age was 56 years (range, 33 to 81 years). Of the 500 patients, only 15 (3 percent) had an isolated perioral rejuvenation procedure, and the remaining 485 (97 percent) had the procedure combined with other facial aesthetic procedures such as face lift [$n = 275$ (55 percent)]; blepharoplasty [$n = 57$ (11 percent)]; lipofilling [$n = 45$ (9 percent)]; rhinoplasty [$n = 17$ (3 percent)]; or other nonfacial aesthetic procedures such as liposuction [$n = 28$ (6 percent)], abdominoplasty [$n = 15$ (3 percent)], breast reduction [$n = 13$ (3 percent)], breast augmentation [$n = 11$ (2 percent)], or a combination of these [$n = 24$ (5 percent)].

Of the 500 patients, 51 had an isolated procedure such as a lip lift [$n = 16$ (3 percent)], a lip augmentation [$n = 15$ (3 percent)], augmentation of the nasolabial folds [$n = 8$ (2 percent)], or skin resurfacing [$n = 12$ (2 percent)]. The vast majority (449 patients) underwent combinations of lip lift and augmentation of the lip and nasolabial fold [$n = 158$ (32 percent)]; lip lift and augmentation of the lip and nasolabial fold with resurfacing [$n = 151$ (30 percent)]; lip augmentation and resurfacing [$n = 72$ (14 percent)]; or lip lift and resurfacing [$n = 68$ (14 percent)]. A lip augmentation ($n = 396$) consisted of either an isolated augmentation of the vermilion [$n = 20$ (5 percent)]; an isolated sharp needle intradermal fat grafting procedure of the bar code [$n = 16$ (4 percent)]; an isolated sharp needle intradermal fat grafting of the white roll and philtrum [$n = 32$ (8 percent)]; a combination of sharp needle intradermal fat grafting of the bar code, white roll, and philtrum [$n = 150$ (38 percent)]; or a combination of all of the above [$n = 178$ (45 percent)]. Skin resurfacing ($n = 303$) consisted of erbium-doped yttrium-aluminum-garnet laser [$n = 206$ (68 percent)] or croton oil peel [$n = 97$ (32 percent)].

The mean length of follow-up for patients in this series was 13 months (range, 3 to 39 months), with 305 patients (61 percent) having a follow-up

period longer than 1 year. There were no reports of expanding hematomas, infections, oil cysts, motor nerve lesions, or wound problems. An unaesthetic stretched scar widening leading to scar revision under local anesthetic occurred in two cases (0.5 percent) of the 393 lip lifts in this series. There were five patients (1 percent) with an asymmetry of the augmented lip ($n = 3$) or nasolabial fold ($n = 2$). Bruising and moderate swelling were seen in all patients and resolved within the normal postoperative period. All patients experienced a temporary loss of sensation at the nostril margin until approximately 4 months postoperatively.

Figures 5 through 7 show the clinical results of different modalities of the described perioral rejuvenation procedures. (See **Figure, Supplemental Digital Content 2**, which shows the perioral area of the patient in Figure 6 at age 29, <http://links.lww.com/PRS/D404>.) Note the synergistic effect of combining different techniques.

DISCUSSION

The ideal proportions between the upper and the lower lip of a young Caucasian woman are different in the frontal versus the profile view. On the frontal view, the vertical height of the vermilion of the upper lip is smaller than that of the lower lip. The ideal proportion is considered to be 1:1.618, the so-called golden proportion.²² On profile view, in contrast, the proportions are inverted, with the upper lip protruding 1 to 2 mm farther anterior than the lower lip.^{9,23} In the aging lip, all these proportions tend to be lost. The clinically appearing ptosis of the upper lip is, in our experience, the only true sagging that takes place in the central part of the face. Vertical photometric analysis of the aging face confirms that the upper lip is the only facial feature that really sags, whereas the rest of the face undergoes an illusionary sagging appearance as a consequence of the deflation of facial soft tissue^{24,25} (Fig. 2). “In and out mimics up and down” because all anatomical landmarks stay exactly in the same place. The upper lip, in contrast, shows an obvious, measurable, and consistent vertical lengthening,^{15–18,26} which can only be corrected by a surgical lip lift.

Attempts to correct aging aspects of the upper lip with volume alone may work in a younger age category, but later on they often result in a disappointing and unnatural appearance.¹⁵ Many patients ask for an isolated upper lip augmentation with the objective of giving the vermilion more vertical height and more anterior projection. Unfortunately, by doing this, the proportions

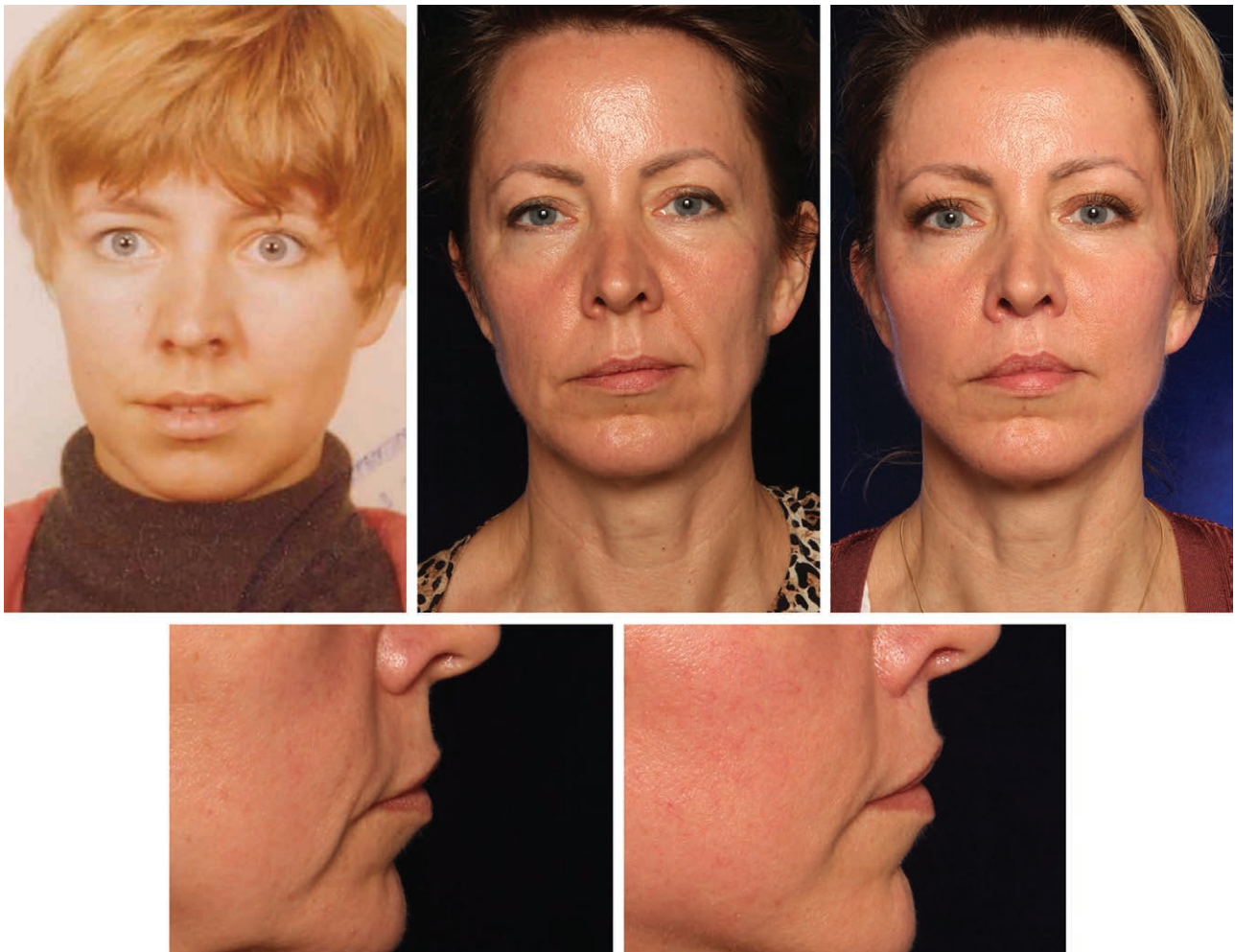

Fig. 5. A 50-year-old woman requesting facial rejuvenation. Apart from the perifacial sagging, she shows centropacial deflation and vertical lengthening of the upper lip. The treatment plan consisted of minimal access cranial suspension lift with two purse-string sutures and centropacial microfat grafting: 1 cc in the upper eyelid, 5 cc in the malar area, 1.5 cc in the left nasolabial fold with subcision, 1 cc in the right nasolabial fold, and 2 cc in the marionette grooves. Sharp needle intradermal fat graft injection was performed in a few vertical rhytides on the upper lip and in the sharp rhytide on the left nasolabial crease. Lip lift is performed with 5-mm resection in the central area. (Above, left) Preoperatively at age 25 years. (Above, center) Preoperatively. (Above, right) Nine months postoperatively. Note the replenishment of the centropacial area and the reconstruction of the youthful proportions of the upper and lower lips.

on the frontal view are disturbed, and this will cause an unnatural appearance.^{13,27,28} Most of the time, the upper and lower lips need to be augmented simultaneously to preserve harmonious proportions. Therefore, we rarely perform an isolated augmentation of the upper lip. Another misconception is attempting to evert the vermilion with volume alone: this often will result in an overfilled appearance with only minimal eversion. An additional lip lift can help to evert the vermilion without overprojecting the lip.

The retrospective analysis of metric changes in soft tissue on magnetic resonance imaging of the aging upper lip¹⁸ has demonstrated that the

upper lip ages with different degrees of tissue lengthening, thinning, and volume loss. Thus, a comprehensive upper lip rejuvenation plan should address these three factors of aging by combining a correctly designed lip lift with adequate volume supplementation in different areas of the upper lip.

The lip lift corrects the (to date) underdiagnosed lengthening of the upper lip. Apart from reducing the vertical height of the upper lip, it also restores the youthful eversion of the vermilion by correcting the inversion and flattening that result from sagging.^{5,26} Combined with volumetric filling of the upper lip, the lip lift works synergistically

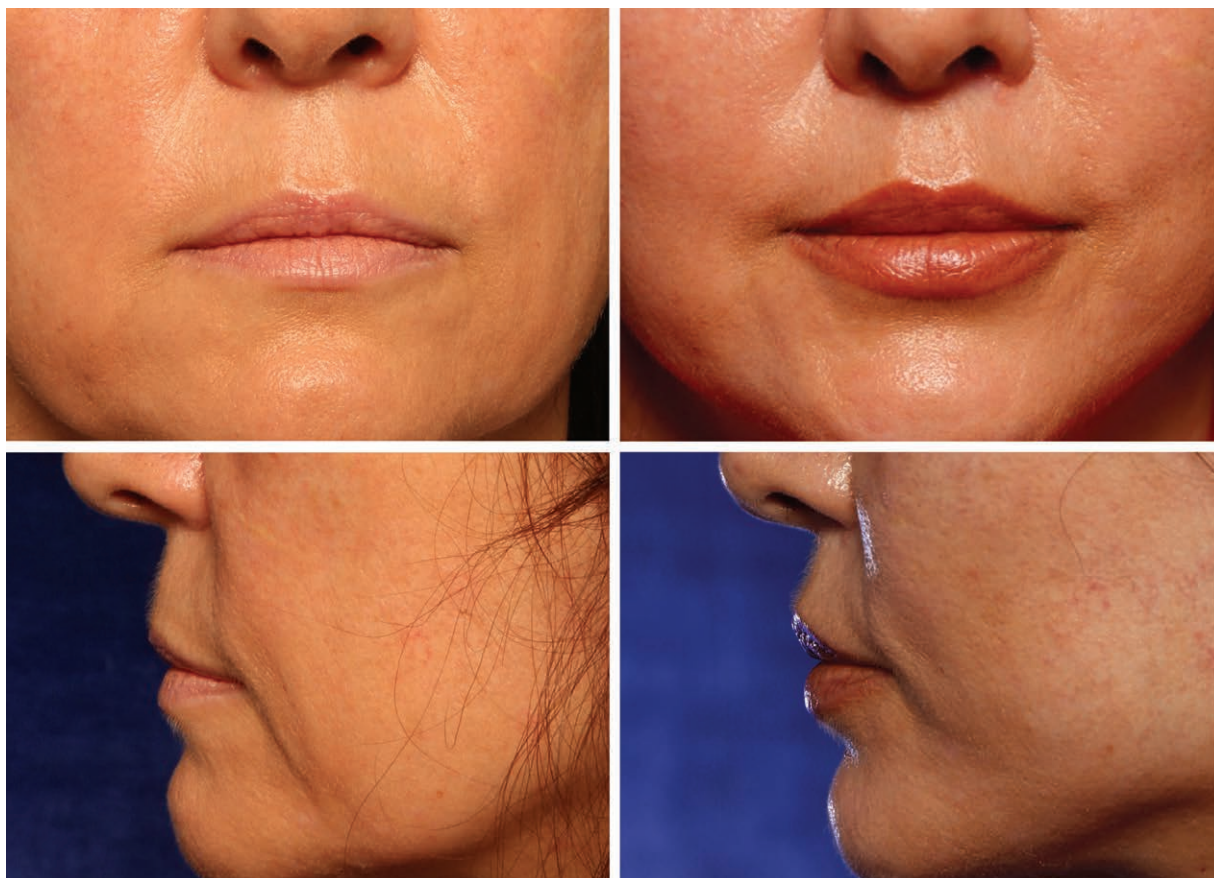

Fig. 6. A 57-year-old patient requesting facial rejuvenation. Apart from the minimal access cranial suspension lift, the nasolabial and marionette grooves were augmented with 2 cc of microfat per side. The upper and lower lips were augmented with 2 cc of microfat per lip. The white roll and philtrum columns were accentuated with sharp needle intradermal fat graft injection to obtain more definition of the lip. The lip lift consisted of a 6-mm subnasal skin resection (see **Figure, Supplemental Digital Content 2**, <http://links.lww.com/PRS/D404>). (Above, left) Preoperative frontal view at age 57 years. (Above, right) Frontal view at 1 year postoperatively. (Below, left) Preoperative profile view. (Below, right) Profile view at 1 year postoperatively. Note the shortening of the upper lip, the volumization of both lips, and the accentuation of the white roll and philtrum columns. On the profile view, the transition from a long convex lip to a short concave lip is obvious.

toward a natural perioral rejuvenation. A lip lift should be performed after proper patient selection with the calculation of the desired length from an old photograph. It should ideally be implemented in almost every multimodal facial rejuvenation plan.

Although presented as a simple skin resection procedure, a meticulously planned resection pattern is essential because a poorly planned skin resection may lead to unaesthetic and disappointing results. The proposed resection pattern has the following advantages:

1. The scar does not transverse the nostril sill but is hidden inside the nostril.
2. The resection above the Cupid's bow is a little wider, resulting in accentuation of the Cupid's bow.

3. The lateral extensions of the resection pattern provide a substantial and necessary lift of the lateral part of the upper lip, avoiding the unnatural central pouting that results from resecting only a central skin fragment.

Several other resection patterns have been proposed in the literature,^{5,26,29,30} which often have small inconveniences, leading to suboptimal, unaesthetic, and/or unnatural results. These could be among the reasons why this procedure was never really popularized.

The results presented in this series show remarkably low morbidity and complication rates. Possible and feared complications are visible scarring and an unnatural aspect of the lip-lift result.^{5,26,30,31} These two unfavorable results are

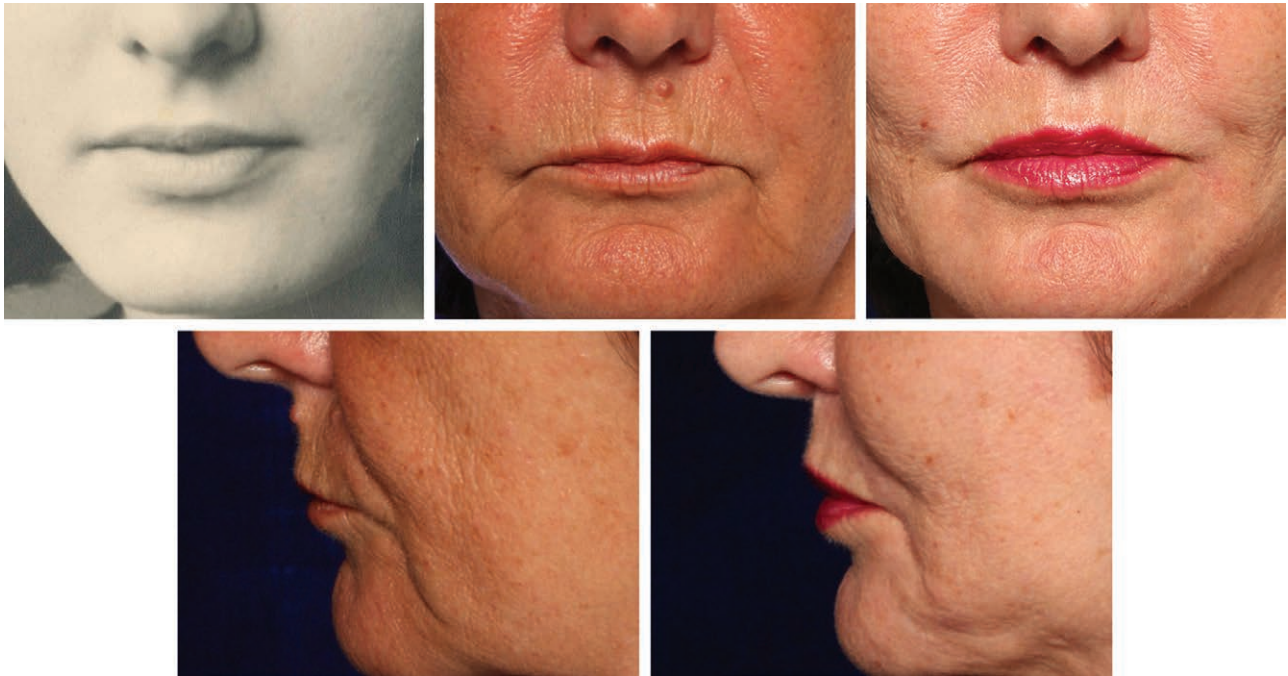

Fig. 7. A 62-year-old woman requesting facial rejuvenation. Apart from the facial lifting procedure, she underwent a centroracial rejuvenation. The perioral treatment plan consisted of microfat grafting of the nasolabial folds with subcision (2 cc per side) and the marionette grooves (3 cc); intramuscular microfat grafting of the vermillion part of the upper and lower lip (3 cc); sharp needle intradermal fat grafting (21-gauge) of the white roll and philtrum columns (2.5 cc); sharp needle intradermal fat grafting (23-gauge) of the vertical rhytides of the upper lip, corners of the mouth, and nasolabial creases (3 cc); light erbium laser resurfacing of the whole perioral area; and a lip lift with resection of 7 mm of subnasal skin. (Above, left) Preoperatively at age 22. (Above, center) Frontal view preoperatively. (Above, right) Frontal view 3 years postoperatively. (Below, left) Profile view preoperatively. (Below, right) Profile view 3 years postoperatively. Note the resemblance with the photograph obtained 40 years previously.

caused by an incorrect design of the excision pattern and/or poor suturing technique.

Theoretically, the upper lip can also be shortened and the vermillion everted by vermillion border excisions. We do not use this technique for purely aesthetic indications because the scar is difficult to conceal and it destroys the delicate anatomical landmark of the white roll, especially if a slight contraction of the scar occurs.

Apart from correction of the vertical lengthening of the upper lip by a lip lift, the atrophy of the whole lip needs to be corrected according to the thinning and volume loss observed on the magnetic resonance imaging study.¹⁸ This includes a deep intramuscular volume augmentation, especially in the caudal part of the lip to compensate the important volume loss in the vermillion and the vermiliocutaneous border and also in the nasolabial folds, especially in the deep pyriform fossa (Ristow space).²¹ Many theories have been proposed for the appearance of the nasolabial fold with aging.^{14,32,33} The deep pyriform fossa is located at the junction of many mimic muscles, including levator anguli oris, levator labii

superioris alaeque nasi, and zygomaticus major and minor. The higher volume loss in this area could be explained by the higher muscle activity in this region, producing a higher degree of subcutaneous fat atrophy, as we can observe this in other parts of the aging centroracial region.²⁰

Finally, the structural changes of the skin quality can be corrected by resurfacing of the lip skin by peeling or laser. Detailed discussion of these techniques is beyond the scope of this article. If combined in one surgical procedure, the most logical surgical sequence is first, the volume augmentation; second, the lip lift; and finally the resurfacing procedure.

CONCLUSIONS

Aging of the perioral area is a multifactorial process; thus, the treatment is multimodal. Based on the results obtained in the retrospective analysis of metric changes in soft tissue on magnetic resonance imaging of the aging upper lip,¹⁸ an evidence-based strategy for surgical rejuvenation of the upper lip is proposed, consisting of a

combination of surgical shortening of the upper lip by a precisely designed lip lift and a differential filling of certain upper lip regions by micro-fat grafting. The correct lip lift design must resect skin in the central part of the upper lip, but we also emphasize the importance of the relation to the lateral extension of the excision to provide a natural and balanced aesthetic outcome. Micro-fat grafting of the upper lip must address the correction of the higher volume loss in the distal part of the upper lip and in the nasolabial fold, especially around the deep pyriform fossa. The combination of these two modalities of lip rejuvenation works synergistically and produces a result that is more than the sum of the different components.

Patrick L. Tonnard, M.D., Ph.D.

Coupure Centrum for Plastic Surgery
Coupure Rechts 164C-D
9000 Gent, Belgium
patrick@coupurecentrum.be

PATIENT CONSENT

Patients provided written consent for the use of their images.

REFERENCES

- Mally P, Czyz CN, Wulc AE. The role of gravity in periorbital and midfacial aging. *Aesthet Surg J*. 2014;34:809–822.
- Lambros V. Commentary on: The role of gravity in periorbital and midfacial aging. *Aesthet Surg J*. 2014;34:823–824.
- Pezeshk RA, Stark RY, Small KH, Unger JG, Rohrich RJ. Role of autologous fat transfer to the superficial fat compartments for perioral rejuvenation. *Plast Reconstr Surg*. 2015;136:301e–309e.
- Guyuron B, Rowe DJ, Weinfeld AB, Eshraghi Y, Fathi A, Iamphongsai S. Factors contributing to the facial aging of identical twins. *Plast Reconstr Surg*. 2009;123:1321–1331.
- Ponsky D, Guyuron B. Comprehensive surgical aesthetic enhancement and rejuvenation of the perioral region. *Aesthet Surg J*. 2011;31:382–391.
- Penna V, Stark GB, Eisenhardt SU, Bannasch H, Iblher N. The aging lip: A comparative histological analysis of age-related changes in the upper lip complex. *Plast Reconstr Surg*. 2009;124:624–628.
- Lévêque JL, Goubanova E. Influence of age on the lips and perioral skin. *Dermatology* 2004;208:307–313.
- Raschke GF, Rieger UM, Bader RD, et al. Perioral aging: An anthropometric appraisal. *J Craniomaxillofac Surg*. 2014;42:e312–e317.
- Perkins SW, Sandel HD IV. Anatomic considerations, analysis, and the aging process of the perioral region. *Facial Plast Surg Clin North Am*. 2007;15:403–407, v.
- Wollina U. Perioral rejuvenation: Restoration of attractiveness in aging females by minimally invasive procedures. *Clin Interv Aging* 2013;8:1149–1155.
- Coleman SR, Grover R. The anatomy of the aging face: Volume loss and changes in 3-dimensional topography. *Aesthet Surg J*. 2006;26:S4–S9.
- Shue S, Kurlander DE, Guyuron B. Fat injection: A systematic review of injection volumes by facial subunit. *Aesthetic Plast Surg*. 2017;42:1–10.
- Rohrich RJ, Pessa JE. The anatomy and clinical implications of perioral submuscular fat. *Plast Reconstr Surg*. 2009;124:266–271.
- Sullivan PK, Hoy EA, Mehan V, Singer DP. An anatomical evaluation and surgical approach to the perioral mound in facial rejuvenation. *Plast Reconstr Surg*. 2010;126:1333–1340.
- Iblher N, Kloepper J, Penna V, Bartholomae JP, Stark GB. Changes in the aging upper lip: A photomorphometric and MRI-based study (on a quest to find the right rejuvenation approach). *J Plast Reconstr Aesthet Surg*. 2008;61:1170–1176.
- Lambros V. Personal communication, 2016.
- Lambros V, Amos G. Three-dimensional facial averaging: A tool for understanding facial aging. *Plast Reconstr Surg*. 2016;138:980e–982e.
- Ramaut L, Tonnard P, Verpaele A, Verstraete K, Blondeel P. Aging of the upper lip: Part I. A retrospective analysis of metric changes in soft tissue on magnetic resonance imaging. *Plast Reconstr Surg*. 2019;143:440–446.
- Zeltzer AA, Tonnard PL, Verpaele AM. Sharp-needle intradermal fat grafting (SNIF). *Aesthet Surg J*. 2012;32:554–561.
- Tonnard PL, Verpaele AM, Zeltzer AA. Augmentation blepharoplasty: A review of 500 consecutive patients. *Aesthet Surg J*. 2013;33:341–352.
- Hartstein ME, Wulc AE, Holds JB, Einan-Lifshitz A. Fat injection into Ristow's space. *Plast Reconstr Surg*. (in press).
- de Maio M, Wu WTL, Goodman GJ, Monheit G. Facial assessment and injection guide for botulinum toxin and injectable hyaluronic acid fillers. *Plast Reconstr Surg*. 2017;140:393e–404e.
- Penna V, Fricke A, Iblher N, Eisenhardt SU, Stark GB. The attractive lip: A photomorphometric analysis. *J Plast Reconstr Aesthet Surg*. 2015;68:920–929.
- Lambros V. Observations on periorbital and midface aging. *Plast Reconstr Surg*. 2007;120:1367–1376; discussion 1377.
- Rohrich RJ, Pessa JE, Ristow B. The youthful cheek and the deep medial fat compartment. *Plast Reconstr Surg*. 2008;121:2107–2112.
- Weston GW, Poindexter BD, Sigal RK, Austin HW. Lifting lips: 28 years of experience using the direct excision approach to rejuvenating the aging mouth. *Aesthet Surg J*. 2009;29:83–86.
- Guerrissi JO, Sanchez LI. An approach to the senile upper lip. *Plast Reconstr Surg*. 1993;92:1187–1191.
- Penna V, Stark GB, Voigt M, Mehlhorn A, Iblher N. Classification of the aging lips: A foundation for an integrated approach to perioral rejuvenation. *Aesthetic Plast Surg*. 2015;39:1–7.
- Bessler S. Combining rhinoplasty with upper lip-lift using a single incision line. *JAMA Facial Plast Surg*. 2018;20:166–167.
- Waldman SR. The subnasal lift. *Facial Plast Surg Clin North Am*. 2007;15:513–516, viii.
- Pan BL. Upper lip lift with a “T”-shaped resection of the orbicularis oris muscle for Asian perioral rejuvenation: A report of 84 patients. *J Plast Reconstr Aesthet Surg*. 2017;70:392–400.
- Yousif NJ, Gosain A, Matloub HS, Sanger JR, Madiedo G, Larson DL. The nasolabial fold: An anatomic and histologic reappraisal. *Plast Reconstr Surg*. 1994;93:60–69.
- Gosain AK, Klein MH, Sudhakar PV, Prost RW. A volumetric analysis of soft-tissue changes in the aging midface using high-resolution MRI: Implications for facial rejuvenation. *Plast Reconstr Surg*. 2005;115:1143–1152; discussion 1153–1155.